

Adenocarcinoma below stapled ileoanal anastomosis after restorative proctocolectomy for ulcerative colitis

Luciano Alessandrini · Anna Kohn ·
Massimo Capaldi · Ilaria Guadagni ·
Andrea Scotti · Roberto Tersigni

Received: 27 January 2011 / Accepted: 1 June 2011 / Published online: 26 July 2011
© Springer-Verlag 2011

Abstract A case of adenocarcinoma arising in a 39-year-old patient after restorative proctocolectomy is reported. The patient underwent an ileal pouch-anal anastomosis with double-stapled technique for severe ulcerative colitis 18 years earlier, without evidence of associated neoplasm or dysplasia in operative specimen. After endoscopic diagnosis of adenocarcinoma, the patient was submitted to excision of the pouch and permanent ileostomy, followed by combined radiotherapy and chemotherapy. Pathology showed an AJCC stage III moderately differentiated mucinous adenocarcinoma. The patient died 24 months after the operation, due to cancer progression. There are 50 reported cases in the indexed medical literature of carcinoma arisen after ileal pouch-anal anastomosis for ulcerative colitis. Twenty-five out of these arose after mucosectomy and hand-sewn anastomosis, and 25 after stapling technique. Furthermore, in 48% of the patients, dysplasia or cancer was already present at the time of the colectomy. The increase of reported cases suggests a routine long-term endoscopic surveillance in patients with long-standing ileal pouches, especially in presence of dysplasia or cancer in the proctocolectomy specimen.

Keywords Ulcerative colitis · Adenocarcinoma · Dysplasia · Restorative proctocolectomy · Ileal pouch-anal anastomosis

Introduction

Restorative proctocolectomy (RPC) with ileal pouch anal anastomosis (IPAA) is currently considered the treatment of choice for ulcerative colitis (UC). The original technique described by Parks and Nicholls in 1978 [1] underwent several modifications in the following years, essentially related to both the configuration of the pouch and the anastomotic technique. The original hand-sewn anastomosis technique included complete removal of diseased mucosa, including the transitional zone, carrying out the anastomosis at the level of dentate line. Later on, a double-stapling ileoanal anastomosis has been proposed. The latter technique is easier to perform and, apparently, provides better functional outcome, although these results have never been confirmed [2]. To perform the stapled anastomosis, it is necessary to leave a tract of transitional mucosa, in which persistent inflammation may end in dysplastic or neoplastic mucosal transformation. In the mucosectomy, however, it is possible to leave small foci of columnar epithelium that may have similar transformations.

Actually, looking carefully at the 50 previously reported cases of adenocarcinoma arising from an IPAA, 50% developed a cancer after a hand-sewn anastomosis and 50% after a stapled anastomosis, with 48% of cases with dysplasia and/or cancer present at the time of colectomy [3–10].

We present the case of a patient who developed an adenocarcinoma of the IPAA 18 years after a RPC performed with double-stapling technique.

L. Alessandrini (✉) · M. Capaldi · I. Guadagni · A. Scotti ·
R. Tersigni
Department of Surgery, General and Oncologic Surgery Unit,
San Camillo-Forlanini Hospitals, C.ne Gianicolense 86,
00152 Rome, Italy
e-mail: lalessandrini@scamilloforlanini.rm.it

A. Kohn
Gastroenterology Unit, San Camillo-Forlanini Hospitals,
Rome, Italy

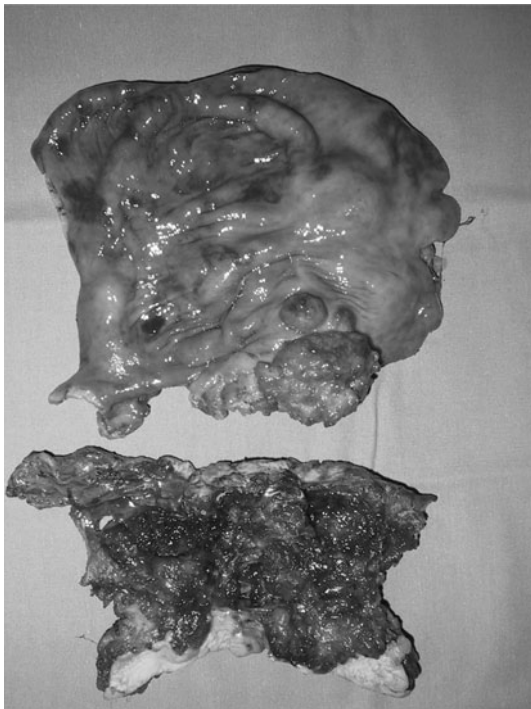


Fig. 1 Gross appearance of surgical specimen

Case report

The patient, a 39-year-old male, was referred to our Surgical Department in August 2002 with a 20-year history of UC. In 1984, due to an episode of severe acute colitis resistant to medical therapy, he underwent a three-stage restorative proctocolectomy with J-pouch construction and double-stapling IPAA. Pathology ruled out either dysplasia or neoplasm after both the operations. After the IPAA, the patient had done well for several years, with a mean stool frequency of 5–6 per day. He underwent periodical endoscopic examination of the pouch, which showed normal or mildly inflamed ileal mucosa. In September 2001, due to an increase in stool frequency, the patient underwent a new endoscopic examination, which revealed a moderate acute pouchitis and a posterior anal fissure. He was treated with topical steroids and systemic antibiotics with partial resolution of symptoms. About 1 month before consulting us, the patient noticed several episodes of gross blood in the stools. Rectal examination and pouch endoscopy revealed a nodular polypoid growth in the anal canal, which proven to be adenocarcinoma on biopsy. At the time of hospitalization, blood biochemistry was normal. The carcinoembryonic antigen level was also found to be normal. Computed tomography scan confirmed the presence of a lesion at the level of the IPAA, involving the surrounding fat tissue, and revealed enlarged retroperitoneal lymph nodes.

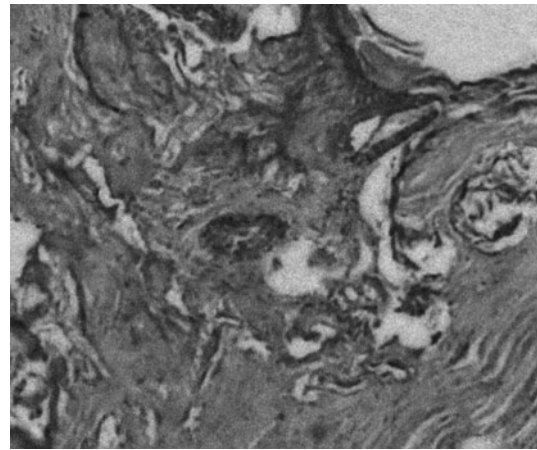


Fig. 2 Histopathologic sample showing mucinous adenocarcinoma (EE $\times 200$)

In August 2002, the patient underwent surgical exploration. At laparotomy, a tumor was present at the level of the IPAA, infiltrating the pouch, the prostate gland and urethra. An abdomino-perineal excision of the pouch and anal canal was performed, with wedge resection of the prostate gland, partial resection of the prostatic portion of the urethra, locoregional lymphadenectomy, and Brooke's terminal ileostomy. The operative specimen consisted of two bowel segments. The first included the ileal pouch and the IPAA, with the presence of an 8 cm long tumor with gelatinous aspect. Tumor growth infiltrated the wall up to the serosa. The second segment, including the rectal stump and the anal canal, was also invaded by a mucinous-like bulking neoplasm, involving the anal transitional zone and the anal canal (Fig. 1). The microscopic sections revealed a moderately differentiated mucinous adenocarcinoma, infiltrating the external anal sphincter and the surrounding soft tissue (Fig. 2). Three out of 15 harvested lymph nodes showed neoplastic invasion. The tumor was staged as pT4 pN1, according to the AJCC 2002 classification. Post-operative course was uneventful and the patient was discharged on 10th post-operative day. Subsequently, the patient received adjuvant chemo-radiotherapy, but unfortunately he progressed to multiple liver metastases, and eventually died 24 months after the operation.

Discussion

Carcinoma arising after IPAA is a rare complication of restorative proctocolectomy for UC but is an important known concern [11, 12]. In February 2009, Branco et al. [3] reported 26 cases of adenocarcinoma of the pouch or outflow tract arisen after IPAA for UC published from 1984 to 2008. After this publication, 24 new cases were

reported in the indexed literature [4–10], with a total of 50 patients affected by carcinoma after IPAA performed for UC. In 24 of these cases (48%), high grade dysplasia or colorectal cancer was present at the time of colectomy. The site of the carcinoma was the pouch in 13 cases (26%), the anal transitional zone (ATZ) in 28 cases (56%), the anal canal in 2 cases (4%), and unclear in 7 (14%). Mucinous poorly differentiated adenocarcinoma was the more commonly observed histology, similar to that reported in IBD-associated tumors. Carcinoma usually occurred in advanced stage, and the prognosis, even after radical surgery and adjuvant therapies, appeared to be poor.

Twenty-five patients developed the tumor after mucosectomy and hand-sewn anastomoses, and 25 after stapled technique. The development of a cancer after hand-sewn IPAA is believed to be due to an incomplete mucosectomy, with persistence of small foci of columnar epithelium, to changes in pouch mucosa due to the chronic inflammation, or to the presence of a previously existing backwash ileitis. Furthermore, in two of the reported cases, the pouch was long-standing diverted for technical reasons with a consequent pouchitis [13, 14]: in one the pouch was excised leaving the anal stump aside [15], and in other a concomitant primary sclerosing cholangitis was present [16]. For some authors, mucosectomy may result in an obstacle to the prevention of post-operative cancer because the burial of rectal isle of mucosa under layers of small bowel into the pouch with difficult to the endoscopic biopsy [3].

The risk of developing a cancer should be increased after stapled IPAA, since the double-stapling technique leaves a 0.5–2 cm long columnar epithelium cuff. The risk of developing a tumor in the transitional epithelium is believed to be due to the development of dysplasia on persistent inflammatory disease, with a 0–16% incidence of dysplastic foci reported in the preserved transitional zone after stapled IPAA. Still, the natural history of dysplasia and its role as a predictor of carcinoma remain controversial. Since the reported incidence of rectal cuff neoplasm after ileorectal anastomosis is 0.5–6% at 20 years and 15–20% after 30 years, a similar theoretical risk of developing a tumor in the preserved transitional zone has been hypothesized. Actually, the incidence of dysplasia or neoplasm in other locations of the colon or rectum. The median time interval from IPAA to cancer is shorter after colectomy for carcinoma complicating UC (3 years) than in non-neoplastic patients (6.5 years) [3]. In some cases, the risk can be increased by a technical error derived from an excessively long residual anorectal cuff.

The main risk factor to develop a cancer after IPAA is the presence of cancer or dysplasia in the operative specimen of the proctocolectomy. In patients without dysplasia or cancer at primary operation, the risk of cancerization

after IPAA increases with time from operation and from the onset of the disease [5]. Dysplasia and aneuploidy are frequently encountered in pouch mucosa, especially in the presence of long-lasting pouchitis, or backwash ileitis. The presence of dysplasia in the ATZ after IPAA is anyway less than 5% and in the majority of cases self-limiting; nevertheless, if repeated biopsies confirm the presence of dysplasia, pouch removal is recommended.

The follow-up periods in the majority of studies on IPAA are no longer enough to assess the true incidence of cancerization [3] and, as in the presented case, many patients with reported carcinoma after IPAA had previously been operated in other hospitals. In the series of 3,203 patients undergoing IPAA for UC at the Cleveland Clinic, the cumulative incidence of cancer at 5, 10 and 25 years was 0.9, 1.3, and 5.1%, respectively [10]. In the multivariate analysis, the only risk factor associated with cancer was a diagnosis of UC-associated cancer or dysplasia, while mucosectomy and chronic pouchitis were not shown to be independent factors [10]. In conclusion, cancer arising from an IPAA for ulcerative colitis is rare and not influenced by the configuration and technique of the anastomosis. However, restorative proctocolectomy does not abolish the risk of tumors associated with UC. The increase of reported cases suggests a routine endoscopic surveillance in patients with long-standing ileal pouches, especially in presence of dysplasia or cancer in the proctocolectomy specimens.

References

1. Parks AG, Nicholls RJ (1978) Proctocolectomy without ileostomy for ulcerative colitis. *BMJ* 2:85–88
2. Schluender SJ, Mei L, Yang H, Fleshner PR (2006) Can a meta-analysis answer the question: is mucosectomy and handsewn or double stapled anastomosis better in ileal pouch anal anastomosis? *Am Surg* 72:912–916
3. Branco BC, Sachar DB, Heimann TM et al (2009) Adenocarcinoma complicating restorative proctocolectomy for ulcerative colitis with mucosectomy performed by Cavitron Ultrasonic Surgical Aspirator. *Colorectal Dis* 11:428–429
4. Candioli S, Manigrasso A, Arcieri S et al (2007) Adenocarcinoma following restorative proctocolectomy for ulcerative colitis: a case report and review of the literature. *G Chir* 28:371–376
5. Das P, Johnson MW, Tekkis PP, Nicholls RJ (2007) Risk of dysplasia and adenocarcinoma following restorative proctocolectomy for ulcerative colitis. *Colorectal Dis* 9:15–27
6. Ruffolo C, Scarpa M, Polese L, Angriman I (2007) Adenocarcinoma after restorative proctocolectomy for cancer in ulcerative colitis. *Int J Colorectal Dis* 22:1557–1558
7. Koh PK, Doumit J, Downs-Kelly E et al (2008) Ileo-anal J-pouch cancer: an unusual case in an unusual location. *Tech Coloproctol* 12:341–345
8. Panier-Suffat L, Marracino M, Resegotti A et al (2009) Anal transitional zone adenocarcinoma following restorative proctocolectomy for ulcerative colitis: case report and review of literature. *Acta Gastroenterol Belg* 72:441–443

9. Ault GT, Nunoo-Mensah JW, Johnson L et al (2009) Adenocarcinoma arising in the middle of ileoanal pouches: report of five cases. *Dis Colon Rectum* 53:538–541
10. Kariv R, Remzi FH, Lian L (2010) Preoperative colorectal neoplasia increases risk for pouch neoplasia in patients with restorative proctocolectomy. *Gastroenterology* 139:806–812
11. Um JW, M’Koma AE (2011) Pouch related dysplasia and adenocarcinoma following restorative proctocolectomy for ulcerative colitis. *Tech Coloproctol* 15:7–16
12. Zmora O, Spector D, Dotan I, Klausner JM, Rabau M, Tulchinsky H (2009) Is stapled ileal pouch anal anastomosis a safe option in ulcerative colitis patients with dysplasia or cancer? *Int J Colorectal Dis* 24:1181–1186
13. Rodriguez-Sanjuan LC, Polavvieja MG, Naranjo A, Castillo J (1995) Adenocarcinoma in an ileal pouch for ulcerative colitis. *Dis Colon Rectum* 38:779–780
14. Iwama T, Kamikawa J, Higuchi T et al (2000) Development of invasive adenocarcinoma in a long standing diverted ileal j-pouch for ulcerative colitis: report of a case. *Dis Colon Rectum* 43:101–104
15. Pedersen ME, Rahr HB, Fenger C, Qvist N (2008) Adenocarcinoma arising from the rectal stump eleven years after excision of an ileal J-pouch in a patient with ulcerative colitis: report of a case. *Dis Colon Rectum* 51:1146–1148
16. Walker M, Radley S (2006) Adenocarcinoma in an ileoanal pouch formed for ulcerative colitis in a patient with primary sclerosing cholangitis and a liver transplant: report of a case and review of the literature. *Dis Colon Rectum* 49:909–912